

■ Multimedia teaching material

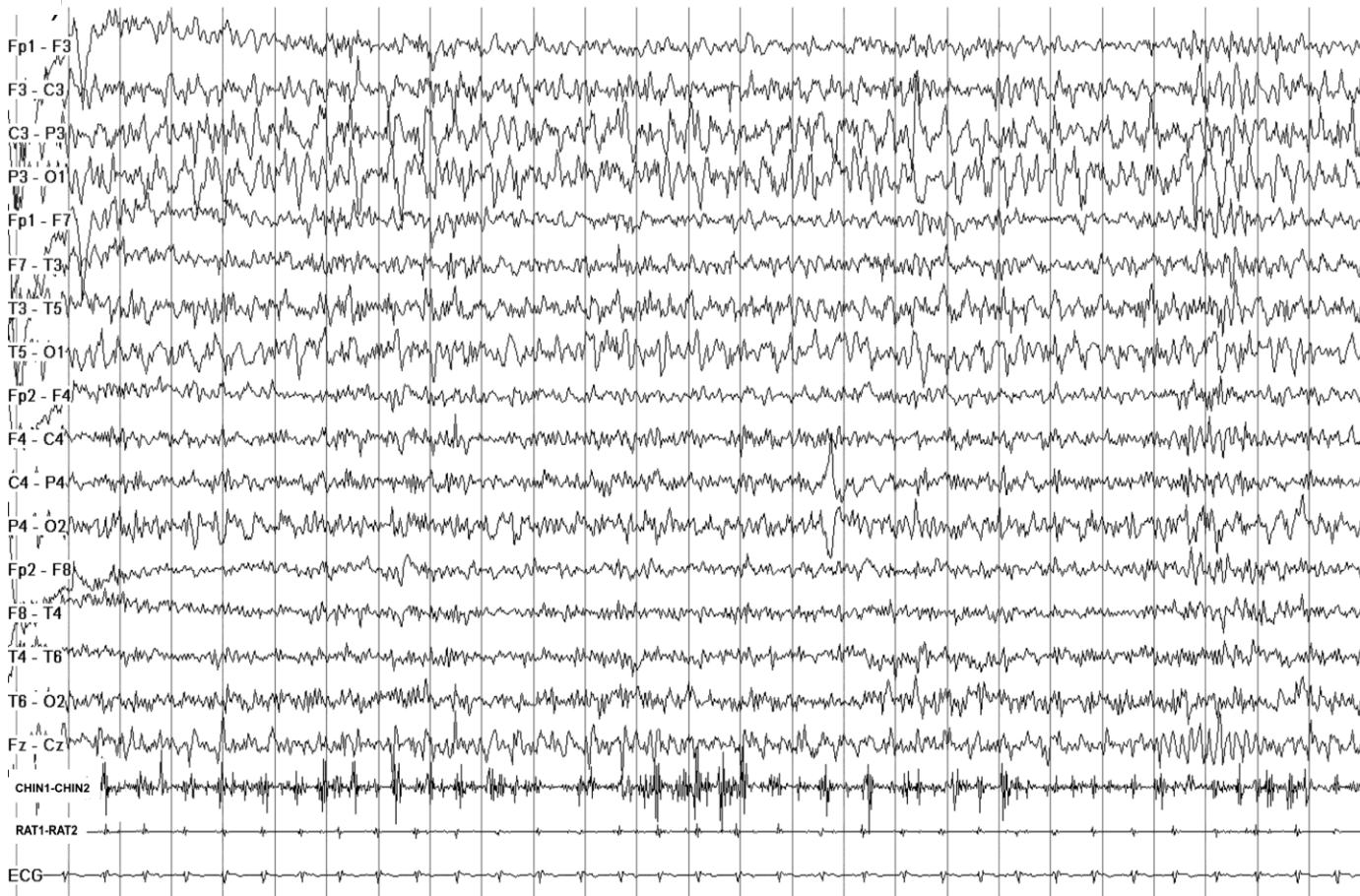
Epileptic Disord 2022; 24 (2): 1-3

Epileptic belly dancing: a video-polygraphic recording

Michele Trimboli^a, Francesco Fortunato^a, Miriam Sturniolo, Franco Pucci, Angelo Labate, Antonio Gambardella

Institute of Neurology, Department
of Medical and Surgical Sciences,
University Magna Graecia of
Catanzaro, Italy

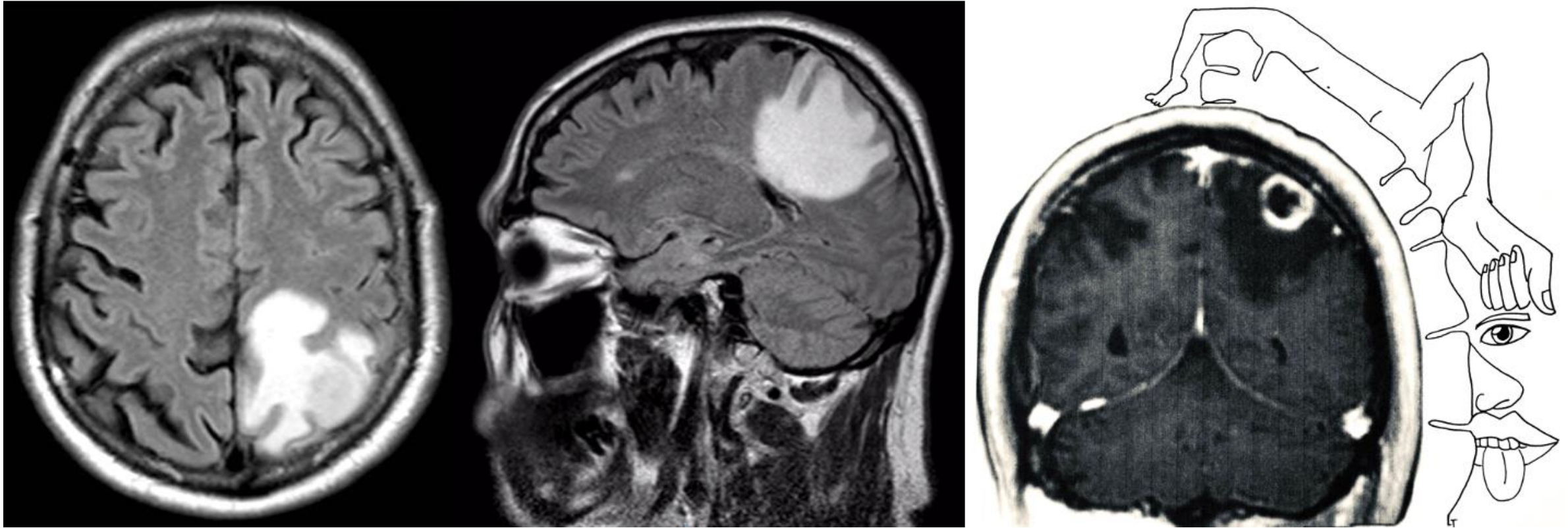
Ictal EEG findings in a 60-year-old patient with a one-year diagnosis of lung adenocarcinoma during an episode of rhythmic contractions of the right rectus abdominis muscle



Note the ongoing 4-6-Hz, rhythmic, sharp activity overlying the left parieto-temporal regions, which is associated with 2.5-3-Hz rhythmic muscle bursts of the right rectus abdominis.

CHIN1-2= right rectus abdominis; *RAT1-2*=left rectus abdominis.

Brain MRI findings



Axial and sagittal fluid-attenuated inversion recovery brain MRI showing hyperintense signal changes around the left central gyrus. Coronal T1-weighted brain MRI with gadolinium reveals a ring enhancement pattern of the parietal lesion. Note also the somatotopic representation of the trunk muscles on the motor homunculus.