

# Alternating hemiplegia of childhood: presentation of two cases regarding the extent of variability

Sema Saltik<sup>1</sup>, Ozlem Çokar<sup>2</sup>, Turkan Uslu<sup>2</sup>, Derya Uludüz<sup>2</sup>, Aysin Dervent<sup>2</sup>

1. Social Security Istanbul Goztepe Education Hospital, Department of Pediatrics  
2. Istanbul University, Cerrahpasa Medical Faculty, Department of Neurology, Division of Child Neurology, Istanbul, Turkey

Received June 6, 2003; Accepted November 27, 2003

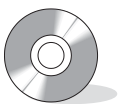**ABSTRACT** – Alternating hemiplegia of childhood is an episodic neurological disorder, the diagnosis of which is solely clinical. In this report, two patients with alternating hemiplegia, one as a representative of the classical picture and the other with unusual features, are presented by video display. Some clinical manifestations and the variability of symptoms are discussed with regard to their place in the diagnosis of the disease. (Published with videosequences)

**KEY WORDS:** alternating hemiplegia of childhood, abnormal ocular movements, hemiplegia, dystonic attacks, tonic seizures, L-dopa

Alternating hemiplegia of childhood (AHC) is a rare disorder characterized by episodic attacks of neurological dysfunction described extensively, elsewhere [1, 2]. Since the diagnosis of the disorder is solely clinical, recognition of extreme cases may improve our understanding of AHC, in particular for handling the clinical complications. In this report, video tapes of two patients, one as an example of the classical picture and the other presenting an early-onset, fulminating course of AHC, are presented, and some clinical symptoms are discussed with regard to their place in the diagnosis of AHC.

**Case 1** is an 8 year-old female who has been followed by us since the age of three. She was healthy until two months of age when short-lasting (~ 10 seconds) attacks of deviation of either or both eyes in any direction,

sometimes with unilateral bobbing, became apparent, many times, daily. By the end of the 4<sup>th</sup> month, alternating hemi-dystonic postural changes developed which increased in number, duration and severity within a few months. Additional symptoms such as opisthotonic posturing, difficulty in swallowing, anarthria and a diffuse tremor of the extremities and the head were present by the age of ten months. A single attack might involve some or all of these events, although with no loss of consciousness. Attacks of alternating hemiplegia, and then, quadriplegia were recognized by 2.5 years of age. At the time of her admission, attacks, involving some or all of the changes mentioned simultaneously or sequentially with range of severity and duration could extend from hours up to three days, during waking only. She was the only child of apparently



**Correspondence:**

Sema Saltik  
Acibadem caddesi No: 146  
Tibas Park Sitesi H Blok Daire: 9  
34660 Uskudar-Istanbul  
Turkey  
Tel: (+ 90) 216 325 82 75  
E-mail: semasaltik@ixir.com

healthy parents with a second-degree consanguinity. A paternal uncle had had two children who had died before six months of age; they had biopsy-proven, spinal muscular atrophy.

The patient had mild mental and motor retardation at her initial examination. The attacks included bizarre movements of either or both eye-balls, such as uprolling, dysconjugate swinging, or nystagmiform changes with rapid blinking and wide opening of the eyes, bilateral pupillary dilatation, in addition to the paretic and dystonic phenomena summarized earlier. Uni- or bilateral hemiplegic attacks with accompanying pyramidal signs would include ipsilateral central-type facial involvement; she was neurologically intact between the attacks (see video). Her speech, which was mildly delayed, would be interrupted during the attacks and she seemed less attentive at these times. Due to the severity of the painful dystonic attacks, L-dopa (125 mg/day) was started as a trial, which led to prompt resolution of the attacks during the one-month treatment period. Although they reappeared later, they were milder and shorter, and much less disturbing. Because of the improvement of the dystonias, attacks of hemiplegia became more prominent. These would be easily triggered by frustration, and also during bathing with hot water. They never took place during sleep, or during the 20-30 minutes following awakening.

Flunarizine, which had been administered for a year, was discontinued due to lack of any apparent effect. During the latest examination at eight years of age, the patient had mild ataxia and moderate psychomotor delay. She was receiving academic support. Hemiplegic attacks and the abnormal ocular movements (AOMs) had become less severe and infrequent over the last two years, and no more dystonic attacks had been observed, according to the parental report.

Biochemical tests covering metabolic and mitochondrial diseases, and a glucose-lactate curve by glucose loading, revealed normal results, as were the results of cranial MRI

and SPECTs during and between attacks. Repeated video-EEGs showed only mild-to-moderate symmetrical or asymmetrical slowing on parieto-occipital regions that became more prominent during attacks. All other characteristics of REM and nREM sleep periods were normal.

**Case 2**, a female infant, six months old, was admitted to our clinic with a diagnosis of 'status epilepticus'. Prenatal and natal histories were unremarkable. She had had three events on the second day of life, all characterized by screaming, tonic extension of the extremities and peri-oral cyanosis. They disappeared after starting phenobarbital that had been given for a month. At 2.5 months of age, the patient had developed frequent, jerky awakenings from sleep, followed by unilateral attacks with a slow, forced-deviation of the head and eyes to the right or the left side accompanied by an ipsilateral tonic extension of the arm and the leg which lasted for a few minutes. They sometimes lasted longer; -i.e. up to 15 minutes when the tonic posturing could become global. EEG recording was obtained during a similar attack, and ictal epileptogenic activity was detected, (see video for this seizure), (Figure 1; ictal EEG). Following an uneventful period lasting a few months, apart from some infrequent, abnormal events such as jerky awakening from sleep followed by gazing to either side, further attacks appeared at six months of age. Clinical manifestations of these events were different from those described above and the patient was referred to our center with the diagnosis of 'status epilepticus'. These recent attacks, which were either spontaneous or triggered by warm baths, started with restless behavior, and several choreiform and dystonic movements took place with increasing severity, reaching a maximum within an hour, and lasting up to three-four hours. Transitory, monocular deviation or bobbing, dysconjugate gaze, mydriasis and left-sided unilateral ptosis were evident. Oral dyskinesias such as sucking, and puckering the lips, frequent and repetitive forced deviation of the eyes and/or the head to either side, unilateral or bilateral tonic or dystonic postur-

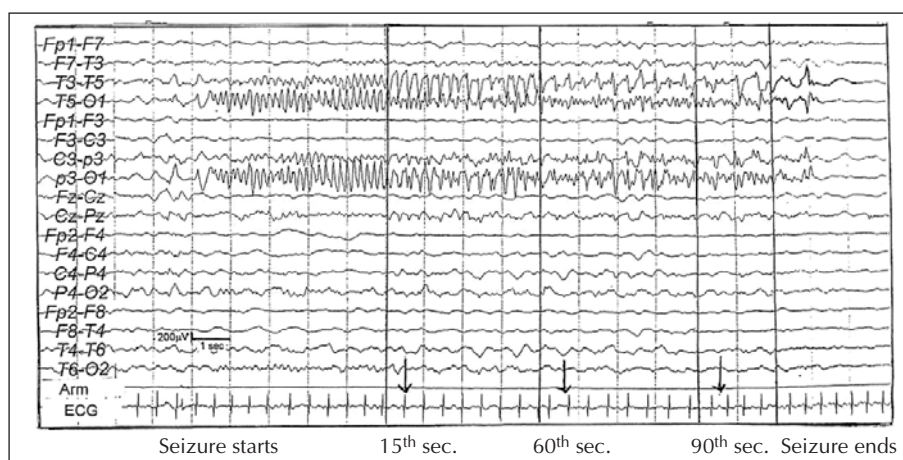


Figure 1. Ictal EEG of the second case during the seizure captured on video.

ing of the extremities and opisthotonus would occur, with increasing severity during an episode, and whistling-like sounds during exhaling would transform to forceful screams. The clinical picture could be referred to as a 'status dyskineticus'. No clinical or EEG signs for epilepsy were present during these episodes, (see sequences from the video). These attacks progressively gained a quasi-continuous character, with variable intensity during the patient's stay in the ward. Additional signs during the observation period included patchy, erythematous skin changes of a migratory and transient character, and areas of hair loss. Stereotypically, she would pull her hair during some attacks. Progressive hypotonia, body ataxia and loss of attentiveness became additional findings associated with a neurological picture that had previously been normal between attacks. By the 6<sup>th</sup> week of admission, respiratory disturbances became apparent during the attacks, and some dyspneic episodes were followed by progressively lengthening periods of respiratory arrest leading to cyanosis. The patient was transferred to ICU, where she died during a laryngeal spasm associated with such an attack, at eight months of age. The abnormal symptoms in this patient disappeared during sleep and re-appeared around 20-30 minutes after awakening, until her transfer to ICU. Normal respiratory functioning during sleep was a major clue for rejection of a previously considered diagnosis of complicating 'bronchiolitis', which had no laboratory confirmation.

No metabolic abnormality was detected by the screening tests, and the cMRI of this case was normal. Repeated EEG recordings after admission revealed moderate slowing of the background activity prominent on the posterior regions, which was either symmetrical or with alternating asymmetry during waking and sleep. Phasic elements of nREM sleep were detectable. Mono- or combined treatment regimens including valproic acid, phenobarbital, clobazam and ACTH provided no benefit. Rectal diazepam was effective initially, but tolerance developed within a few days.

## Discussion

Since the diagnosis of AHC depends solely on the clinical features, it would seem useful to analyze the symptoms and signs in detail in order to better recognize the distinct characteristics, especially in conditions with a fulminating course where the hemiplegic attacks characteristic of the disorder might not have yet developed, as in our second case. The first case presented here fulfills all the diagnostic criteria for AHC in accordance with the clinical description by Aicardi *et al.* [1], and staging proposed by Mikati *et al.* [2]. Therefore, it may be referred to as a typical case of AHC, whereas the second case displays considerable differences from those of the classical picture. When summarized, the clinical features and the course of the disease

presented here, may be categorized in 4 stages: **stage 1** includes a few neonatal attacks of either an epileptic or non-epileptic nature; **stage 2**, starting at 2.5 months of age, is marked by alternating attacks, at least one of which was of an epileptic nature as confirmed by ictal-EEG; **stage 3** starts at six months with spontaneous or triggered, long-lasting episodes marked by abnormal ocular movements and uni- or bilateral dyskinetic-dystonic movements and posturing, with mild autonomic changes; finally, a progression in the duration and severity of the episodes, dominated by autonomic changes with respiratory disturbances leading to death, may be regarded as **stage 4**. Postural hypotonia and ataxia, and also a decrease in awareness were steadily progressive features of the clinical picture. All of these features seem to point to the diagnosis of AHC [1]. The absence of hemiplegic attacks may cloud the diagnosis. On the other hand however, such an absence may not be an unexpected condition in isolated cases with short survival, since hemiplegias are known to succeed abnormal ocular movements and dystonias in the sequence of clinical symptoms, and may not be seen within the first year of life [2, 3]. Disappearance of attacks during sleep, and their bathing-triggered character [2] may provide further evidence in support of the diagnosis.

This report draws attention to the challenging fact that the clinical features of AHC may be distributed over a wide-spectrum, ranging from easy-to-recognize to atypical ones. The presence of epileptic seizures as the initial features in the evolution of AHC may be misleading. A mis-diagnosis of Todd's paralysis may be made for the hemiplegic attacks in such cases, and the unilateral dystonic episodes may be interpreted as tonic seizures, as was stated previously [2]. Our second case was treated as 'status epilepticus' during the dystonic attacks. Ictal EEG may have provided differential diagnostic value in such conditions. Epileptogenic activity was recorded during a true epileptic seizure mimicking unilateral dystonic posturing, and no EEG abnormalities were present during the later episodes, which we then referred to as 'status dyskineticus'.

In AHC, signs of autonomic involvement may easily be overlooked both by the parents and the physicians. No particular autonomic sign, apart from pupillary dilatation during some attacks, was encountered in the first case. The second patient however, exhibited patchy areas of reddening of the skin and the scalp that were spontaneously reversible, but which could last for a few hours. She also had developed areas of hair loss. These might have been either due to the hair-pulling seen during the episodes of dyskinesia, or to vaso-motor involvement, or both. Paroxysmal changes in respiration and vaso-motor function have been reported before [2]. Respiratory symptoms, when present, may necessitate preventive measures as they represent a serious hazard. In the second case, death

occurred within six weeks after the onset of respiratory abnormalities that progressed rapidly.

There were several differences between the clinical presentations of these two cases of AHC. Episodes in the first case within a range of a few hours to three days, were characterized by alternating or bilateral, repetitive AOMs, dystonias, plegic attacks lasting up to a few minutes, interrupted with normal periods of varying duration. Spontaneous termination was the rule for all of the attacks. The attacks in the second case however, had developed a different clinical profile within months. In stages 1 and 2, there were simple alternating versive tonic or dystonic episodes, sometimes with secondary bilateralization. These would cease spontaneously. In stage 3 however, no return to the normal condition occurred during the long-lasting attacks involving AOMs, dyskinetic and dystonic movements, as well as early autonomic changes. The attacks would consistently take place in a crescendo pattern, ending with intra-rectal diazepam administration early on, and with exhaustion leading to sleep, later in the course. Therefore, they were considered as a period of 'status'.

The second major difference was in the course of the disease. Symptoms in the second case started very early in life and the clinical profile was a steady progression within months, with increasing severity of both the dystonic episodes and the respiratory involvement. Such cases of AHC with very early-onset and fulminating course, may go unrecognized, especially when patients have a short life span due to severe autonomic involvement.

The permanent and prompt amelioration in the severity of the painful dystonic attacks during and after the short-term L-dopa trial in the first case may deserve discussion elsewhere as regards therapeutic aspects of AHC, and may be interesting if supported by similar experiences.

AHC seems to be a disorder presenting with AOM, extrapyramidal manifestations, pyramidal tract and cerebellar involvements, epileptic seizures, autonomic nervous dysfunctions of an episodic nature, with intra- and inter-individual variability, and with a tendency for some symptoms to resolve in the long-run, while others tend to

become more or less stabilized. Autonomic abnormalities may be subtle or life threatening. Normalization of respiration during sleep in these conditions may be of the utmost importance as a clue for diagnosis. Absence of ictal findings associated with the epileptic-like attacks, may be of additional value to avoid a mis-diagnosis of an epileptic disorder. □



## Video commentary

### Case 1

Interattack period: normal, voluntary movements during neurological examination.

- First part: right hemiparesis
- Second part: dystonic posturing
- Third part: left hemiparesis
- Fourth part: quadriparesis
- Fifth part: axial hypotonia, palpebral and ocular dysfunctions and oral automatisms.

### Case 2

First part: partial adverse seizure (see EEG in figure 1)

Second part: normal waking behaviour

Third part: a long lasting attack characterized by unresponsiveness, dyskinetic movements, ocular, and palpebral (left) abnormalities. Severity increases in a steady, progressive fashion. Breathing irregularities, screaming, a flexor spasm and opisthotonic posturing are seen.

## References

1. Aicardi J, Bourgeois M, Goutières F. Alternating hemiplegia of childhood: Clinical findings and diagnostic criteria. In: Andermann F, Aicardi J, Vigeveno F(eds). *Alternating hemiplegia of childhood*. New York: Raven press, 1995: 3-18.
2. Mikati MA, Kramer U, Zupanc ML, Shanahan RJ. Alternating hemiplegia of childhood: Clinical manifestations and long-term outcome. *Pediatr Neurol* 2000; 23: 134-41.
3. Bourgeois M, Aicardi J, Goutières F. Alternating hemiplegia of childhood. *J Pediatr* 1993; 122: 673-9.